

In Search of the Ideal Female Umbilicus

Stefan B. Craig, M.S., M.D., Mary S. Faller, B.S., M.D., and Charles L. Puckett, M.D.

Columbia, Mo.

The umbilicus is essential to the aesthetic appearance of the abdomen. However, little research exists on what characterizes an aesthetically pleasing umbilicus. Often, the plastic surgeon is called on to reconstruct the umbilicus. Although a variety of reconstructive methods are available, no real standards define the appearance of an aesthetically pleasing umbilicus. To ascertain the characteristics of an aesthetically pleasing umbilicus, a photographic analysis was undertaken using 147 female participants between the ages of 18 and 62 years.

Each subject's age, height, and weight were recorded. Photographs of each participant's umbilicus were then taken from 30 cm and 50 cm away. The photographs were reviewed by the authors, and each umbilicus was categorized on the basis of size, shape, hooding, or protrusion. The photographs were then reviewed by a panel and given a score between 1 and 10 to rate attractiveness. Using linear regression analysis, the effects of body mass index, shape, hooding, and umbilical protrusion on attractiveness were assessed.

The T- or vertically shaped umbilicus with superior hooding consistently scored the highest in aesthetic appeal, whereas the presence of any degree of protrusion and a horizontal orientation or distorted shape detracted from the score. Those with a large umbilicus tended to score consistently lower than those with a smaller configuration. A desirable goal in umbilical reconstruction is, thus, to create a small T or vertically oriented umbilicus with the addition of a superior hood or shelf. (*Plast. Reconstr. Surg.* 105: 389, 2000.)

The umbilicus is essential to the contour of the abdomen. It helps define the medial abdominal sulcus and contributes to the shapely curve of the inferior abdomen. Its absence leads to an unnatural abdominal appearance, but an abnormally shaped or misplaced umbilicus may draw undue attention to the central abdomen. Currently, a number of plastic surgery procedures may alter the shape and location of the umbilicus. To reconstruct or improve the umbilical appearance, the ideal must be known.

The umbilicus itself has been described as a depressed scar surrounded by a natural skin fold that measures 1.5 to 2 cm in diameter and lies anatomically within the midline at the level of the superior iliac crests.^{1,2} It is generally flat and vertically oriented in young individuals, and later it develops hooding and deepening of the stalk as fat accumulates along the deep fat pocket that surrounds the umbilicus.^{3,4} A transverse orientation generally occurs after childbirth; however, aging in combination with weight gain will contribute to a deeper umbilical stalk and an overall widened appearance.⁵

A wide and deep umbilicus and an exceedingly small umbilicus are considered unattractive. The presence of outward protrusion (an "outie") is also considered unappealing.¹ Characteristics thought to be appealing include a moderately small umbilical size with an overall vertical orientation. The presence of a superior hood or shelf is also thought to add a youthful, more pleasing appearance to the abdomen.⁶⁻⁸ Although many plastic surgeons undoubtedly have their own sense of ideal, to our knowledge, no one has critically examined the physical characteristics that contribute to an appealing umbilicus.

SUBJECTS AND METHODS

To ascertain the characteristics of an appealing umbilicus, a photographic analysis of the umbilicus was undertaken in 147 women between the ages of 18 and 62 years. Each participant was asked to complete a questionnaire and sign a photographic release form before enrollment. Those who were pregnant or had undergone any prior abdominal surgery were excluded from the study.

Each participant's age, height, and weight

From the Division of Plastic Surgery, University of Missouri. Received for publication March 31, 1999; revised July 8, 1999.

Presented at the Annual Meeting of the Plastic Surgery Research Council in Loma Linda, California, April 7, 1998, and the Annual Meeting of the American Society for Aesthetic Plastic Surgery in Los Angeles, California, May 3, 1998.

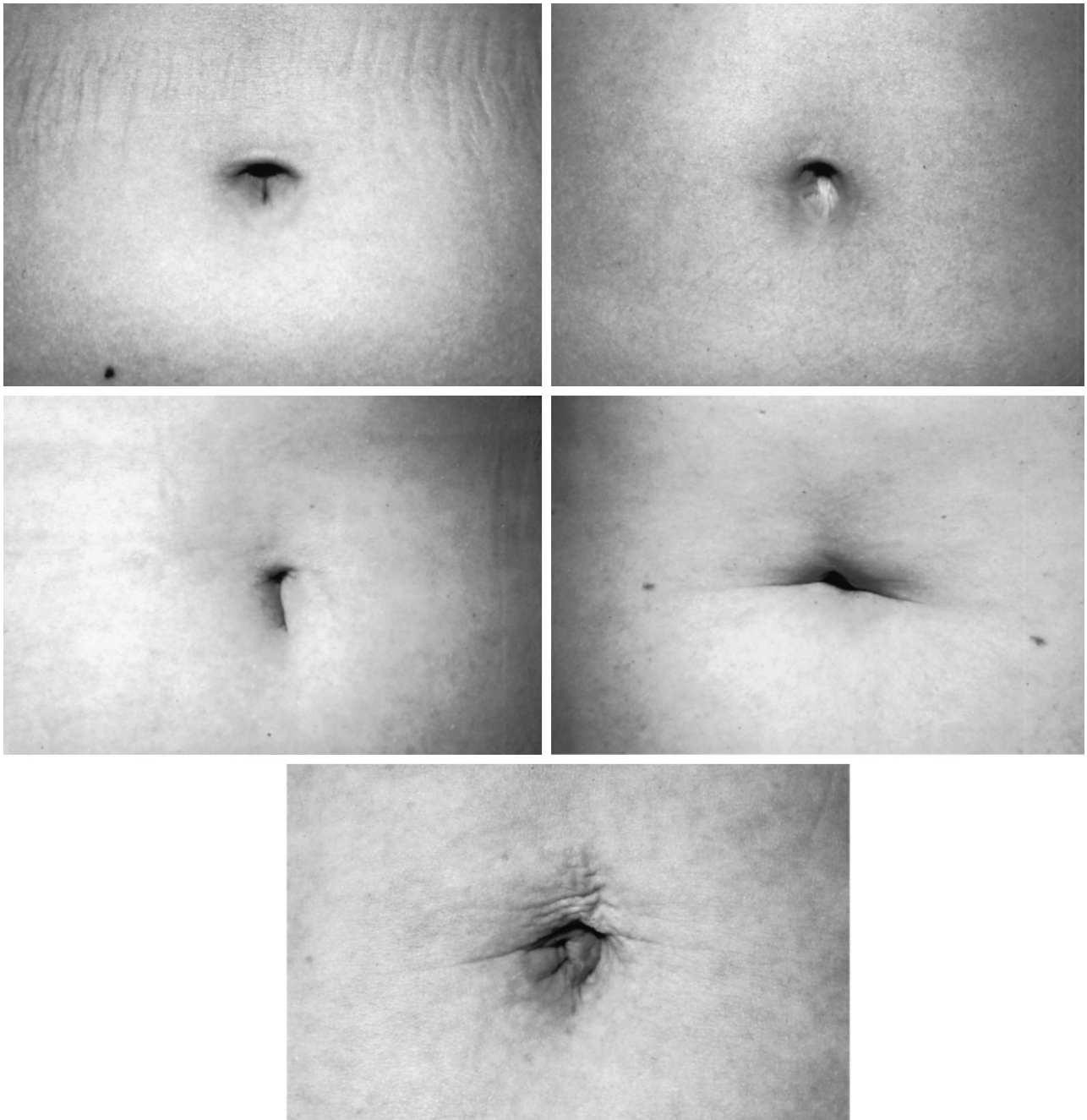


FIG. 1. Umbilical shapes and their frequency of occurrence. (*Above, left*) A T-shaped umbilicus was present in 37 percent of subjects ($n = 54$); (*above, right*) an oval-shaped umbilicus was present in 22 percent ($n = 32$); (*center, left*) a vertically shaped umbilicus was present in 17 percent ($n = 25$); (*center, right*) a horizontally shaped umbilicus was present in 14 percent ($n = 21$); and (*below*) distorted shapes were seen in 10 percent ($n = 15$).

were recorded. Color photographs of the umbilicus were then taken from a distance of 30 and 50 cm using a standard 35-mm camera with a 60-mm lens. Photographs from 30 cm away included only the umbilicus, whereas photographs from 50 cm away incorporated the entire abdomen.

The photographs were then individually an-

alyzed by the authors, and each umbilicus was categorized on the basis of shape, hooding, umbilical protrusion, and size. A total of 21 examiners (15 men and six women) were asked to individually review the near (30 cm) photographs and assign a score between 1 and 10 for each umbilicus. A score of 1 was considered very unappealing, whereas a score of 10

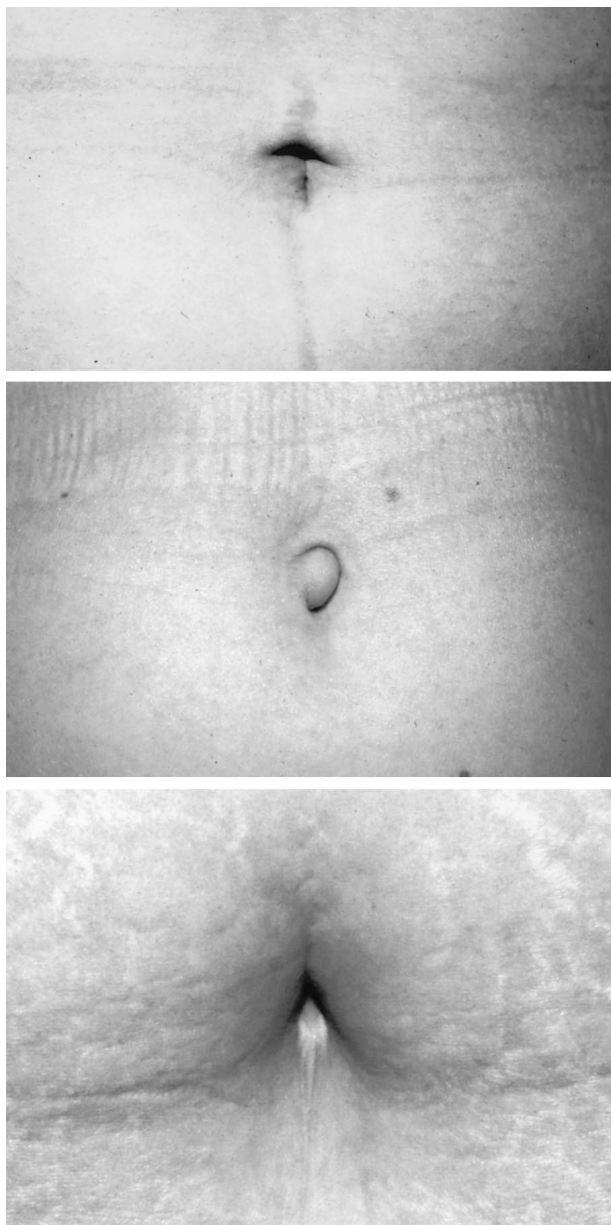


FIG. 2. (*Above*) Umbilical hooding characterized by a superior hood or shelf occurred in 77 percent of subjects ($n = 113$); (*center*) umbilical protrusion outside central concavity was seen in 10 percent ($n = 15$); and (*below*) an excessively large umbilicus was seen in 11 percent ($n = 16$).

was very appealing. Once the near photograph scoring was complete, the far photographs were then reviewed and scored in a similar manner. These data were then statistically analyzed.

To help account for individual differences in body habitus, the body mass index (kg^2/cm) was determined for each participant. To determine if a participant's body mass index biased either the near or far scores, Pearson correlation coefficients were tabulated for the near

TABLE I
The Influence of Shape on Umbilical Score

Umbilical Shape	Predicted Near Score Mean	Predicted Far Score Mean
T-shaped	5.24*	5.17*
Vertical	4.72*	4.76*
Oval	4.68*	4.39
Horizontal	4.20	4.06
Distorted	3.26	3.26

* $p = 0.01$.

Scoring was done on a scale of 1 to 10 (least appealing to most appealing).

and far score differences and the body mass index. The individual effects of shape, hooding, umbilical protrusion, and size on umbilical score were assessed using linear regression analysis.

RESULTS

In total, 147 women with an average age of 29 years were photographed. Their average height was 166 cm (5'5"), and their average weight was 62 kg (138 pounds). The average body mass index for all participants was $22.72 \text{ kg}/\text{m}^2$.

Results of the photographic analysis showed that the average near and far scores for all participants were 4.62 and 4.49, respectively. The highest individual score average was 8.29, which was seen in a near photograph, and the highest far score average was 7.14. The lowest individual near score average was 1.38, and the lowest far score was 1.33.

Overall, 37 percent of the participants possessed a T-shaped umbilicus. The oval shape was seen in 22 percent of participants, and 17 percent had a vertically oriented umbilicus. Fourteen percent of participants had a horizontal shape. Those umbilici did not fall into one of these four shape categories were classified as distorted. Ten percent of those photographed fell into this classification (Fig. 1).

Umbilical hooding, as determined by a superior hood or shelf, was evident in 77 percent of those photographed (Fig. 2, *above*). Umbilical protrusion outside the central concavity of the umbilicus was seen in 10 percent of the participants (Fig. 2, *center*). Eleven percent of the women had an appreciably large umbilicus (Fig. 2, *below*).

When differences in near and far scores were compared with an individual's body mass index, a nonsignificant correlation of 0.054 ($p = 0.526$) was seen, suggesting that the examiners

did not score those with larger abdomens lower because of their abdominal size.

However, when the body mass index was compared with the near and far scores individually, a significant negative correlation of -0.371 for the near score was seen, whereas the far scores showed a similar negative correlation of -0.431 ($p = 0.0001$), inferring that the more obese participants would score lower.

Through linear regression analysis, the T-shaped umbilicus was found to be most appealing in both the near and far photographs. The T, vertical, and oval near scores were significantly higher than either the horizontal or distorted scores. In the far photographs, the T and vertically shaped umbilicus scored significantly higher than the remaining three shapes (Table I).

By again using linear regression analysis, the effects of hooding, protrusion, and umbilical size were discovered. The presence of hooding added, on average, 0.8 points to the score. However, if one possessed either umbilical protrusion or a large umbilicus, the score concomitantly dropped 1.70 and 2.0 points, respectively.

DISCUSSION

Within our study population, the most commonly seen umbilical shape was T-shaped. This was followed by the oval, vertical, horizontal, and distorted shapes, respectively. The majority of subjects photographed, demonstrated a superior hood and possessed a small umbilicus without protrusion.

Those women who were heavier tended to have a larger, more transversely oriented umbilicus, whereas the umbilici in thinner subjects had a more oval or vertical orientation. Interestingly, the size of a subject's abdomen did not seem to influence umbilical scoring. Obese subjects were scored in a similar manner to the other subjects, regardless of whether only the umbilicus itself was seen in the photograph or the entire abdomen could be visualized.

Umbilical score was influenced by several factors. Umbilical protrusion (an outie) was unappealing. Those subjects with protrusion showed, on average, a 1.7-point drop in score.

Furthermore, the presence of an appreciably large umbilicus had a strong negative influence on the umbilical score, leading to an average decrease in score of 2 points. Hooding, however, had a strong positive influence, and raised the umbilical score 0.8 points on average.

CONCLUSIONS

These data suggest that the most aesthetically pleasing umbilicus is small in size, T or vertical in shape, and possesses a superior hood or shelf. Those characteristics found to be unappealing include a large overall umbilical size, a horizontal or distorted shape, and the presence of umbilical protrusion. In reconstructing the umbilicus, plastic surgeons should strive to attain these attractive characteristics and incorporate a modest size, with a superior shelf or hood and a T or vertical shape. Further research is ongoing to attempt to define the technique that will result in this appearance.

Charles L. Puckett, M.D.
University of Missouri
Division of Plastic Surgery
One Hospital Drive
Columbia, Mo. 65212
puckettc@health.missouri.edu

REFERENCES

1. Baroudi, R. Umbilicoplasty. *Clin. Plast. Surg.* 2: 431, 1975.
2. Dubou, R., and Ousterhout, D. K. Placement of the umbilicus in an abdominoplasty. *Plast. Reconstr. Surg.* 61: 291, 1978.
3. Psillakis, J. M., Appiani, E., and de la Plaza, R. *Color Atlas of Aesthetic Surgery of the Abdomen*. New York: Thieme Medical Publishers, 1991. Pp. 6-7.
4. Markman, B., and Barton, F. E., Jr. Anatomy of the subcutaneous tissue of the trunk and the lower extremity. *Plast. Reconstr. Surg.* 80: 248, 1987.
5. Teimourian, B., and Marefat, S. Body Contouring with Suction-Assisted Lipectomy. In M. Cohen (Ed.), *Mastery of Plastic and Reconstructive Surgery*, Vol. 3. Boston: Little, Brown, 1994. Pp. 2186-2200.
6. Hodgkinson, D. J. Umbilicoplasty: Conversion of "outie" to "innie." *Aesthetic Plast. Surg.* 7: 221, 1983.
7. Miller, M. J., and Balch, C. M. "Iris" technique for immediate umbilical reconstruction. *Plast. Reconstr. Surg.* 92: 754, 1993.
8. Rohrich, R. J. Body contouring (overview). *Select. Read. Plast. Surg.* 7: 1, 1995.